

# RESECTION AND RECONSTRUCTIVE-PLASTIC SURGERY INTREATMENT OF EXTENDED AND MULTIFOCAL CICATRICAL TRACHEAL STENOSIS



Otabek Eshonkhodjaev<sup>1</sup>, Shukrat Khudaybergenov<sup>1</sup>, Ortikali Irisov<sup>1</sup>, Nasretudin Tursunov<sup>1</sup>

1 - Republican Specialized Centre of Surgery, Tashkent, Uzbekistan

2 - Tashkent Medical Academy, Tashkent, Uzbekistan

## ABSTRACT

**Background:** Obstetric complications developing at antiphospholipid syndrome are serious medical-social problem. Seeking of the treatment methods sets conditions for urgency of the article reviewed. Enzyme preparations are widely applied for treatment of women with fecundity disorder and hemorheology changes. Research objective was in clinico-laboratorial evaluation of Serrata drug impact in antiphospholipid syndrome in women with reproductive losses of Andijan state. **Methods:** Data of 43 women in the non-pregnancy state with reproductive losses (RL) in past history with revealed APS had been studied by us. **Results:** Thus, conducted therapy with Serrata was conductive to haemostasis. Conducted researches confirm the safety of application. **Background.** Main issues of treatment of patients with cicatricial stenosis of trachea (CST) are to increase its efficacy and safety, as well as to determine indications and contraindications for circular resection and reconstructive interventions on the trachea in patients with extended lesions of trachea, with stenoses involving subvocal cords part of larynx and well as multifocal narrowing of the trachea which could improve treatment results and quality of life of patients, to gain recovery and reduce disability and mortality.

**Material and methods.** One hundred two patients aged from 11 to 62 years with CST were surgically treated. Stenotic site length in patients varied from 0,3 to 7 cm. Most frequently (64,2%), CST length of more than 2 cm was observed. In critical and decompensated stenosis with diameter of CST up to 5 mm with the threat of asphyxiation by the first stage we used endoscopic laser and electric destruction of constriction followed by restricted zone bouging. If long-term rehabilitation was necessary and in case of absence of the conditions to the implementation of circular tracheal resection, we used tracheal stents. Circular resection of the trachea was performed in 24 patients. In case of contraindications, 28 patients underwent reconstructive plastic surgery with dissection the stenosis, excision of scar tissue and formation of trachea lumen in T-tube. After removing T-tube plasty of anterior tracheal wall and of soft tissues of the neck defects was performed using local tissues and grafts with microsurgical techniques.

## UDC CODE & KEYWORDS

■ UDC: 612.2 ■ Cicatricial narrowing of the trachea ■ Tracheal resection ■ Post-intubation benign tracheal stenosis ■ tracheal stenosis after tracheostomy ■ Tracheal plasty ■ Extensive and multifocal stenosis

## INTRODUCTION

Cicatricial tracheal stenosis is a disease associated with the replacement of normal tracheal wall by a rough scar tissue which narrows the lumen of the respiratory tract. This process can be combined with the loss of the carcass function of tracheal wall and the appearance of tracheomalacia sites (Brichet, 2002; Gyusan, 2004; Kubishkin, 2006). Prolonged tracheal intubation and tracheostomy performed according to vital indications in ICUs in order to conduct adequate ventilation are the main etiologic factor and iatrogenic cause of tracheal stenosis in significant portion of the patients (Fridel, Wurst et al., 2001; Kirasirova & Ejova, 2004; Gasanov et al., 2010; Serebrennikova, 2011). Currently, tendency towards the increase of the number of patients with cicatricial tracheal stenosis (CTS) is being observed (Vijigina et al., 2001; Lafutkina, 2007; Leontyev & Korotkevich, 2012).

Presently, a circular resection of the trachea with the "end to end" anastomosis is the most effective form of treatment that allows removing the diseased segment and restoring patency of the airways. In textbooks, there are few works on how to suture trachea-tracheal anastomoses depending on the forms of tracheal stenosis (Grillo, 2003; Cordos et al., 2009; Tatur, 2011; Yaitsky & Gerasin, 2012). Safety of the operation also remains as an issue. Postoperative complications of circular tracheal resection constitute 6.2-28%, and postoperative mortality according to some data can reach up to 10% (Wright et al., 2004; Abbasidezfouli & Akbarian, 2009; Bisenkov, 2012).

An issue of importance is to determine the indications and contraindications for tracheal resection in patients with extended lesions of the respiratory tract. Previously, the only possible safe method of treatment for those patients was a life long cannula-carriage or a long-term treatment through repeated palliative trachea-plastic operations that did not always lead to good functional results (Rusakov, 2006; Parshin, 2010; Vereschagina, 2010).

Another category of patients who present a difficult challenge for treatment are the ones with multifocal lesions of the trachea (Parshin, 2007; Gavrilo, 2009; Kotiv, 2012). Their characteristic feature is the presence of stenosis at two levels with an intact tracheal wall between them. Treatment of these patients requires a special treatment tactics. According to textbooks, there is a tendency to maximally broader application of resection methods of treatment. Circular resection of the trachea is considered as the most optimal treatment option for cicatricial stenoses.

A special group is consisted of patients in whom the stenosis is extended to the subglottic regions of the larynx. High laryngo-tracheal stenoses include CTS of the upper third of the trachea involving the subglottic regions of the larynx which extends from the lower edge of the cricoid cartilage to the vocal cords. This localization is indeed the most difficult pathology for a radical treatment in thoracic surgery (Zenger et al., 2006; Novikov et al., 2008). Application of reconstructive surgery

also doesn't always allow eliminating the restriction. Due to the anatomical relationships in this region, radical surgery carries a risk of damaging the vocal cords, recurrent laryngeal nerves and disruptions of the framing of distal parts of the larynx. Postoperative period after such operations has its own characteristic features. Often they are caused by respiratory disorders due to oedema of subglottic part of the larynx. There is no single consensus about the appropriateness of the laryngo-tracheal resection incicatricialstenosis of subglottic part of the larynx and the upper third of the trachea. And while some surgeons still use it, the others refuse to do so (Benoit Bibas & Roberto Bibas, 2005; Carretta et al., 2009; D'Andrilli et al. 2008; Han, 2009).

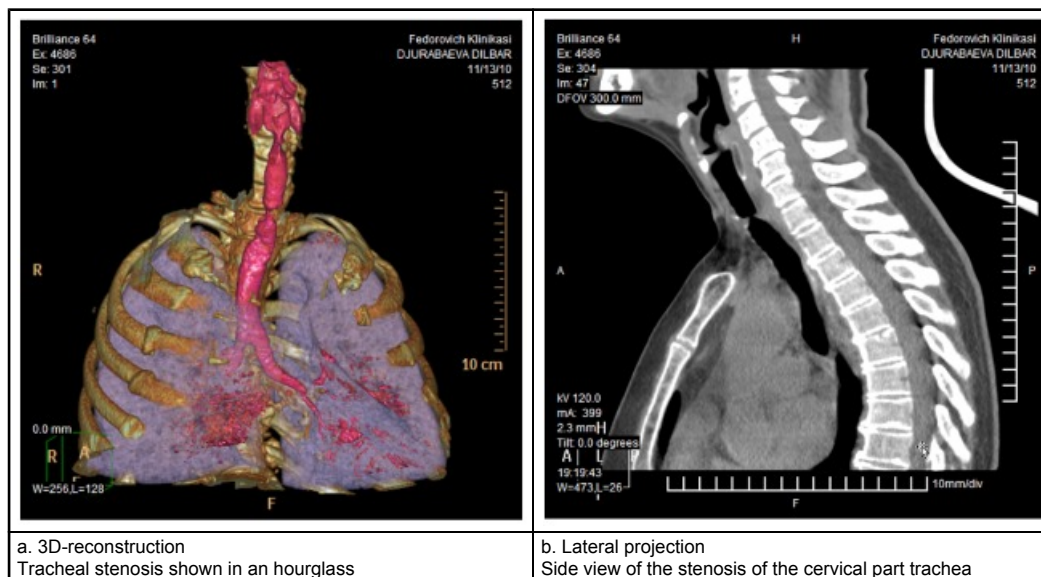
All the above-mentioned facts indicate the actuality and social significance of complex treatment of trachea-laryngeal, extended and multifocal tracheal stenosis which lead to an improvement of the outcomes and quality of life of patients, recovering working abilities and reducing disability and mortality.

The aim of the study is to determine the efficacy of resection and reconstructive- plastic surgical interventions in the treatment of extended and multifocal cicatricialtracheal stenosis.

**Materials and Methods.** A differentiated approach based on complex surgical treatment of CTS is being practised in the Department of Surgery of the lungs and mediastinum of the Republican Specialized Centre of Surgery named after academician V. Vakhidov since 2008, using methods of endoscopic intraluminal surgery, as well as plastic and reconstructive interventions which were performed on 102 patients. Clinical management tactics of patients is performed using a diagnostic- treatment algorithm. On admission of patients with suspected tracheal stenosis, a thorough medical history is collected with emphasis on data about surgical interventions or resuscitations with intubation or tracheostomy, in order to determine the stage of the stenosis. Furthermore, in order to confirm the stenosis and assess the degree and extension, localization and activity of the process, all patients are undergone instrumental examinations including fibro-bronchoscopy, when necessary- a rigid bronchoscopy under intravenous sedation, MSCT of the chest with the capture of the cervical region with 3D- reconstruction (Fig. 1) of the trachea and virtual bronchoscopy (Fig. 2). Patients' ages ranged from 11 to 62 years. Localization of stenoses were as follows: in the upper third of the trachea in 32 (47.1%) cases; 9 (13.2%) patients had the stenosis of the thoracic part of the trachea; trachea-laryngeal localization with the affliction of subglottic part of the larynx and upper third of the trachea was found in 19 (18.6%) patients; a combined lesion of the larynx and the thoracic part of the trachea was present in 4 (5.8%) patients; and in 5 cases there was as carry restriction of the cervical and thoracic parts of the trachea (7.35%).

CTS was complicated by oesophageal- tracheal fistula in 2 patient. In 6 (5.8%) of the patients there was a complete scarry obliteration, i.e. an imperforation of the tracheal lumen by scar tissue above tracheostomy cannula. 8 patients were admitted from other medical centres with postoperative anastomotic stenoses of the trachea after circular resection. The extension of stenotic part in patients varied from 0.3 to 7 cm. Most frequently (64.2%) CTS with extension of more than 2 cm were observed.

Figure 1: a. CT multiplanar reconstruction of trachea, b. Cicatricial stenosis of the cervical part of the trachea

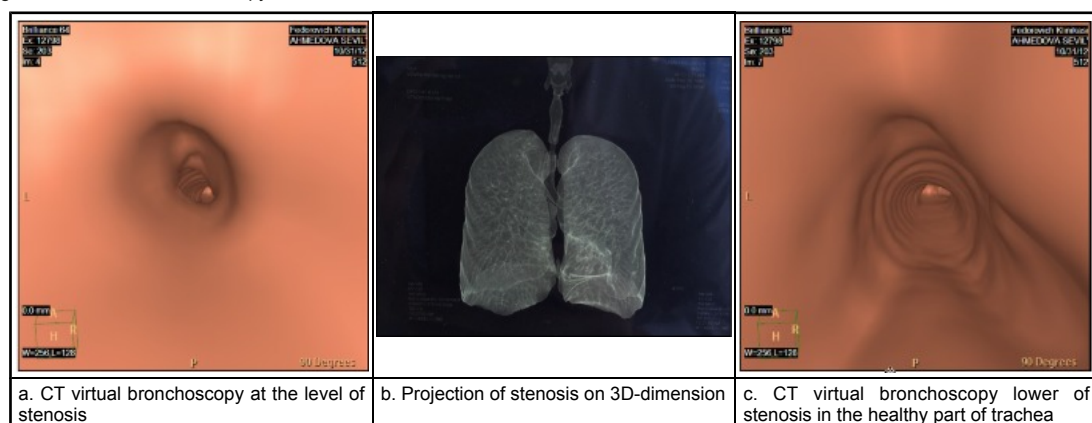


Source: Authors

## Results and Discussion

After establishing the parameters of cicatricial tracheal stenosis including localization, degree and extension, considering the presence or absence of the tracheostomy cannula, and also depending on the patient's general condition, various methods of luminal restoration were performed. In cases of critical and decompensated stenosis the diameter of up to 5 mm with the risk of asphyxiation, patients underwent endoscopic laser- or diathermo-destruction of the stenosis followed by bougienage of the stenotic zone as the first step. Bougienage was performed in conditions of an operating room or an ICU under local anaesthesia using intubation tubes of increasing diameter conducted by a fibro-bronchoscope beyond the zone of restriction with the exposure of a few minutes.

RESECTION AND RECONSTRUCTIVE-PLASTIC SURGERY INTREATMENT OF EXTENDED AND MULTIFOCAL CICATRICAL TRACHEAL STENOSIS  
Figure 2: CT Virtual bronchoscopy of stenotic area

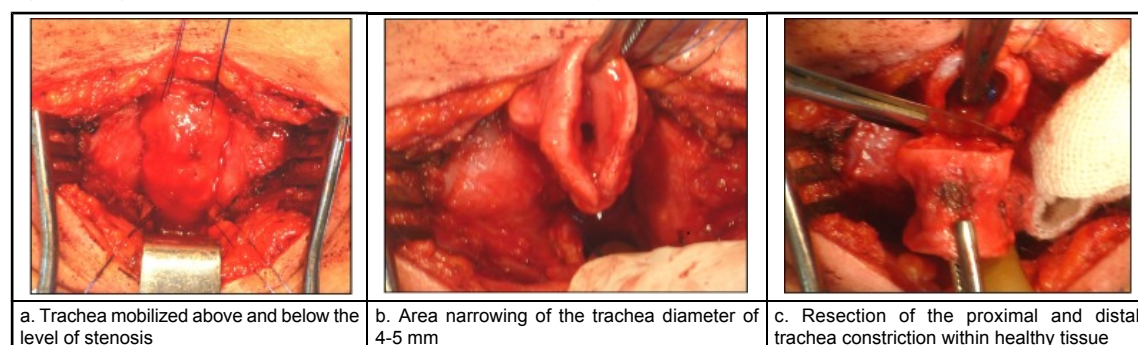


Source: Authors

When contraindications were present for the implementation of circular tracheal resection, after restoring the tracheal lumen endoscopically, endotracheal stents of Dumont were installed at the site of scarry deformation with the aim of long-term dilation (n = 12) for a period of 6 to 12 months (on average 8 months). In this instance, good results were achieved in 5 patients, stenosis was stabilized, tracheallumen was saved without tendency to restenosis. 2 patients had complications in the form of migration and displacement of the stent to the lower third of the trachea in one patient and to the right main bronchus in the other. The stents were removed. The patients underwent circular tracheal resection.

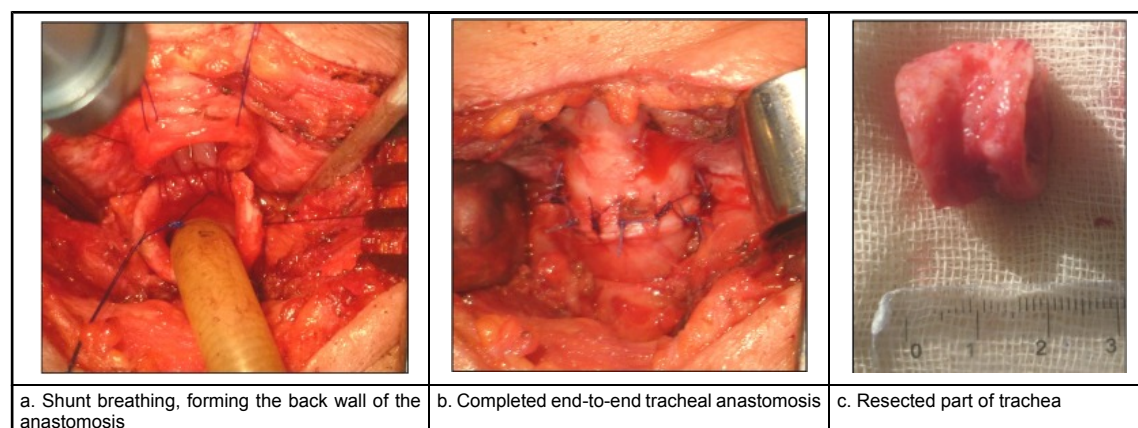
When conducting circular tracheal resection (n = 24), we used cervical collar-like access (12) on patients with the stenoses of subglottic part of the larynx and upper third of the trachea, and sternotomy access was used in cases of localization of stenosis in the mid and lower third of the trachea in 8 patients, of which in 3 cases T- shaped longitudinal-transverse sternotomy was performed in order to access the mid third of the trachea. In cases of extended restrictions, for the purpose of mobilizing the trachea sufficiently, we used cervico- sternotomy access (in 4 patients).

Figure 3: Stages of circular resection of the upper third of the trachea by cervical approach



Source: Authors

Figure 4: a. Stages of circular resection of cervical part trachea, b. Forming of anastomosis, c. Shunt-breathing. Completed anastomosis

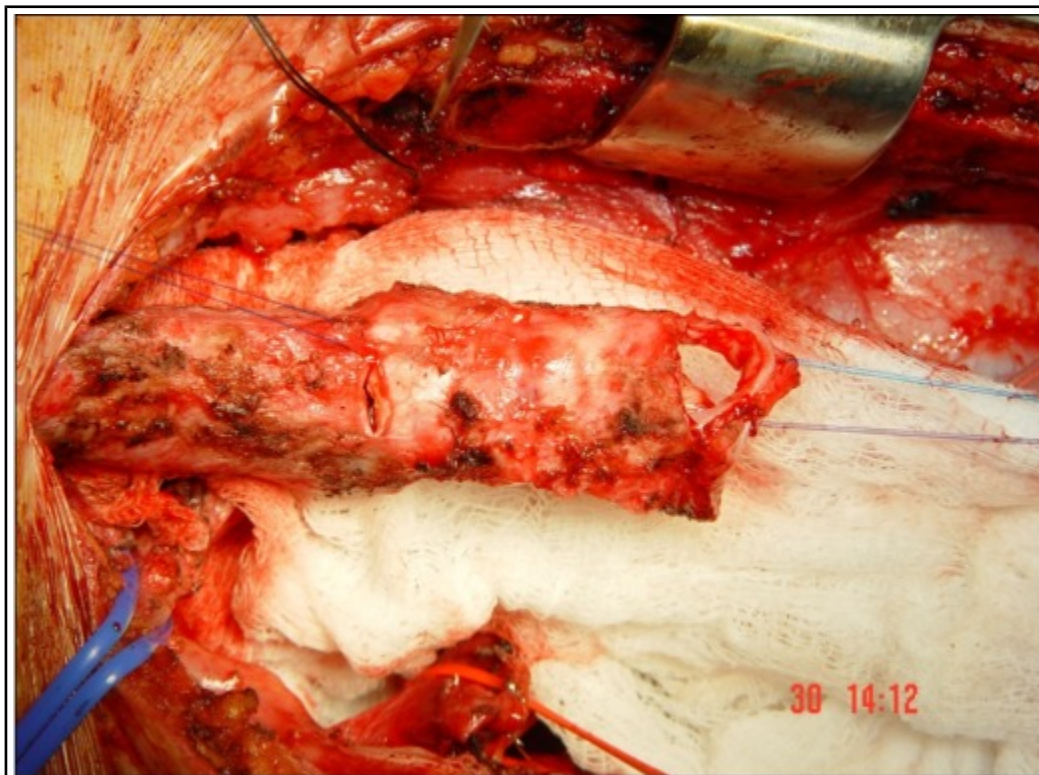


Source: Authors



The trachea was isolated from peritracheal scarry adhesions, taken on ligature tapes above and below the stenotic zone predefining the restriction zone by illuminating and marking the resection zone with needles under the control of fibre-bronchoscopy. A sufficient mobilization of the trachea above and below the level of the lesion was performed in order to avoid and minimize tension in the region of anastomosis. After opening the trachea, the system of "shunt- breathing" was established within the shortest time (Fig. 3 and 4). Oro-tracheal tube was pulled back into the subglottic space for this period. We also used high-frequency mechanical ventilation via a catheter conducted through the stenotic zone by fibre-bronchoscope or intraoperatively after opening the lumen of the trachea. Extension of the resected fragments of trachea was 2.0 to 5.5 cm (Fig.5).

Figure 5: Extended resection of the trachea by sternotomy access



Note: Stage of extended circular resection of thoracic part of trachea by sternotomy access. 7 cm of trachea mobilized. Distal part cut. Ready to cut the proximal part

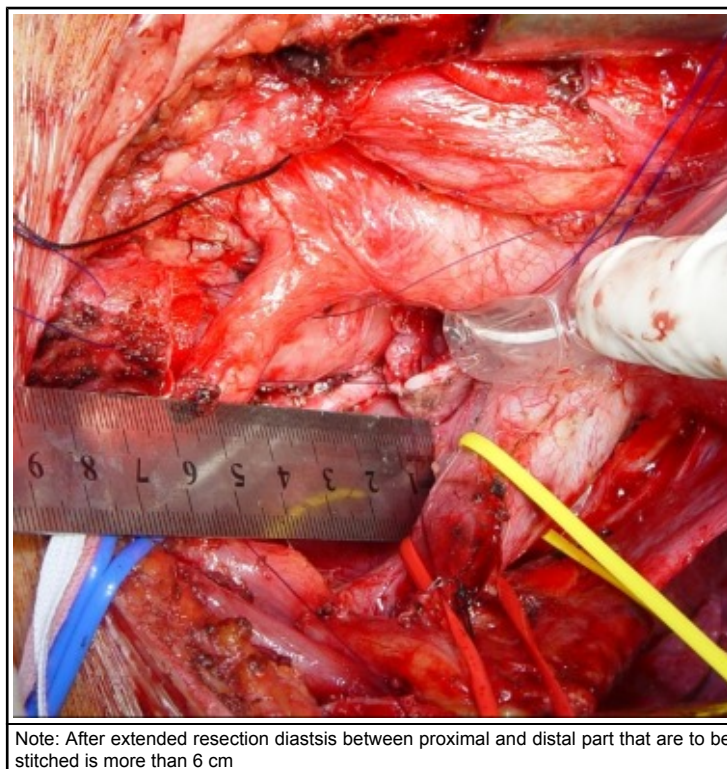
Source: Authors

In this instance, the diastasis between each segments ranged from 3.0 to 7 cm (Fig.6). Monofilament thread-biosyn3/0 was used to form a continuous entwining suture of the posterior (membranous) wall of the anastomosis of the trachea. Fixating nodal sutures were created on the lateral walls. Further, the formation of the lateral and anterior walls of the trachea was performed using the same absorbable monofilament thread-biosyn3/0 forming nodal sutures which were left outside relative to the tracheal lumen (Fig.7).

Before retracting the sutures of the anterior wall of the anastomosis the "shunt- breathing" was removed and orotracheal tube was conducted under fibre-bronchoscopic control. Water probe was performed for leak proofness of the anastomosis. Fibrobronchoscopic control of the anastomosis area and sanation of bronchi was performed before removing the "shunt-breathing" and conducting an orotracheal reinforced endotracheal tube. Anastomosis area was drained for 2 days. The patient's head was led to the thorax and fixed with sutures between the chin and anterior chest wall for the period of 14 days in order to reduce the tension of the anastomotic sutures.

The stage of inserting T-tube. The "shunt-breathing" - intubation tube № 5.5 is conducted through the perpendicular external knee of the T-stent.

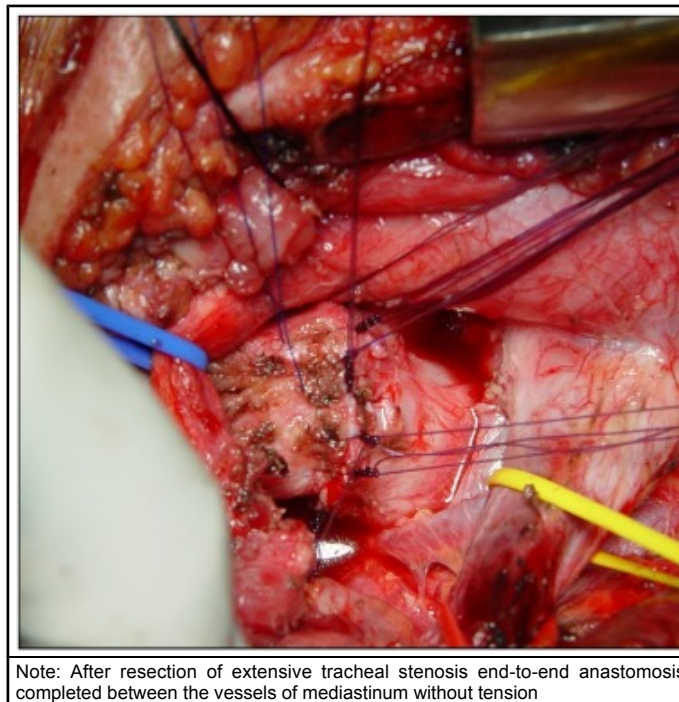
When contraindications were present due to comorbidities, mostly of neurological character, patients underwent reconstructive plastic surgery with the dissection of the stenotic area, excision of scar tissues and the formation of the tracheal lumen on a T- stent (Fig. 8 ). In 5 patients such operations were performed due to the presence of multifocal stenosis of the trachea at different levels with the existing tracheostomy on admission, and the presence of intact areas of the trachea between the stenotic zones. T-stent was also established in 5 patients due to the presence of combined stenosis of the trachea and complete luminal obliteration of the subglottic part of the larynx above the stoma. After forming a sufficient lumen and creating permanent stoma, T-stent was inserted into the trachea with a prior measurement of its proximal and distal ends, considering its location in the subglottic part and in doing so, eliminating the possibility of touching the vocal cords which would be a risk for granulation formation on the ligaments.



Source: Authors

After appearance of an adequate consciousness and awakening of the patient, the tube was removed, the sealing membrane of the stent was closed, the patient was able to breathe through natural airways and a clear phonation was recovered. Formation of the lumen on a T-stent was conducted for 4-12 months, depending on the results achieved.

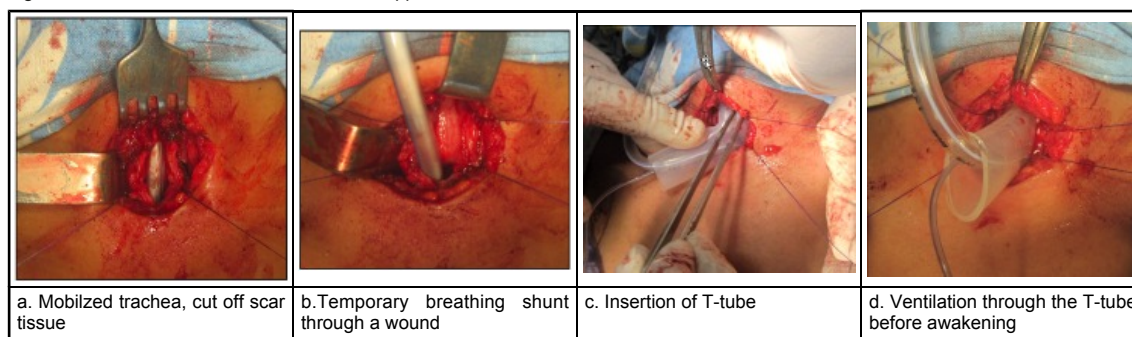
Figure 7: Completed anastomosis between the vessels of the mediastinum



Source: Authors

<http://www.journals.cz>

RESECTION AND RECONSTRUCTIVE-PLASTIC SURGERY INTREATMENT OF EXTENDED AND MULTIFOCAL CICATRICAL TRACHEAL STENOSIS  
Figure 8: Plastics of cicatricial stenosis of the upper third of the trachea with the formation of the lumen on a T-tube



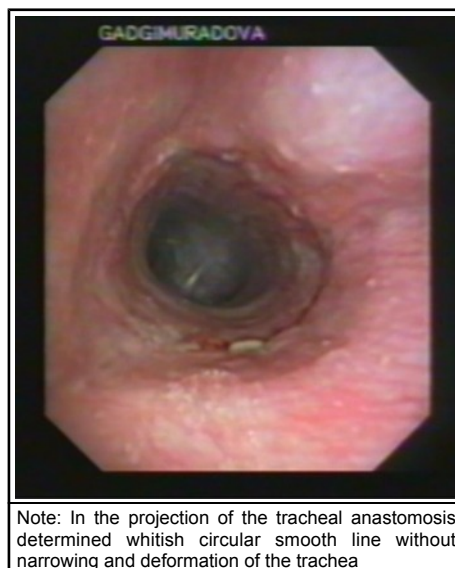
Source: Authors

Evaluation of long-term results of the treatment we have carried out on the basis of complaints of patients, given the data of endoscopic and radiological studies on the following scale:

- Good result - a complete restoration of normal lumen of the trachea or stabilization of stenosis in the compensated stage (no stridor and dyspnea at rest and during exercise, the diameter of the narrowing of the trachea more than 0.7 cm without progression of stenosis) does not require endosurgical or open surgical correction.
- A satisfactory result - subcompensated form of stenosis (free breathing at rest, stridor during forced breathing in and dyspnoea on exertion, which corresponds to the diameter of the narrowing of 0.5 to 0.7 cm), and the indications for endosurgical or open surgical treatment were evaluated individually, depending on the general condition of the patient and the presence of contraindications.
- Unsatisfactory result - recurrence of decompensated form of stenosis requiring repeated endosurgical treatment, reconstructive surgery or leaving (or installation) of tracheostomy tube and lack of phonation.

Long-term results of treatment evaluated and studied in a period of 6 months to 5 years in 89 (87.3%) patients. 13 patients continues to one of the stages of complex treatment. The patients are under dynamic endoscopic control. Good results were achieved in the treatment of 71 patients (79.8%)(Fig. 9), satisfactory - in 12 (13.4%), unsatisfactory results in 6 (6.7%) patients.

Figure 9: Photo of tracheal anastomosis



Source: Authors

## CONCLUSION

1. In patients with cicatricialtracheal stenosis a multimodal approach should be implemented depending on the degree, localization, extension and levels of the stenosis, with the consideration of the severity of comorbidities, using complex endosurgical, resection and reconstructive- plastic methods of treatment.
2. In cases of extended cicatricial tracheal stenosis with the process involving more than 30-50 % of the trachea, up to 6-7 cm, a circular tracheal resection can be performed under conditions of sufficient mobilization at the required levels.
3. Multifocal restrictions of the trachea, and also the ones combined with stenosis of the subglottic larynx, should be treated with the formation of the lumen on a T- stent.



### Competing Interest

The authors declare that they have no competing interests.

### Author's Contribution

OE performed endoscopic and surgical procedures. SK carried out reconstructive operations and coordinated and helped to draft the manuscript. OI participated in the design of the study. NT participated in the collection of archival material. JB participated in the examination and treatment of patients, helped with design articles and translated it into the English language. All authors read and approved the final manuscript."

### Acknowledgement

The authors are acknowledge the contribution to Professor Feruz Nazirov for his comprehensive help and support to the study. There was no funding for the present study.

### REFERENCES

- Abbasidezfouli A., Akbarian E. (2009). The etiological factors of recurrence after tracheal resection and reconstruction in post-intubation stenosis. *Interactive Cardiovascular and Thoracic Surg.*, 9: 446 - 449.
- Benoit J. Bibas, Roberto A. Bibas. (2005). A New Technique for T-Tube Insertion in Tracheal Stenosis Located Above the Tracheal Stoma. *Ann. Thorac. Surgery*, 80: 2387 - 2389.
- Bisenkov LN. (2012). Surgery of cicatricial stenosis of trachea. S. Petersburg: «Logos»; 144 (book in russian).
- Brichet A., Ramon P., Marquette C. H. (2002). Post-intubation tracheal stenosis and ruptures. *Réanimation*, 11 (1), P. 49-58.
- Cameron D. Wright, Hermes C. Grillo, John C. Wain, Douglas J. Mathisen. (2004). Anastomotic complications after tracheal resection: Prognostic factors and management. *J. Thorac. Cardiovasc. Surg.*; 128: 731 - 739.
- Carretta A., Casiraghu M., Melloni G., Bandiera A. et al. (2009). Montgomery T-tube placement in the treatment of benign tracheal lesions. *Eur. J. Cardiothorac. Surg.*; 36: 352 - 356.
- Cordos I., Bolca C., Paleru C. (2009). Sixty tracheal resections - single center experience. *Interactive Cardiovascular and Thoracic Surgery*, 8: 62 - 65.
- D'Andrilli A., Ciccone A.M., Venuta F., Rendina E.A. (2008). Long-term results of laryngo tracheal resection for benign stenosis. *Eur. J. Cardiothorac. Surg.*, 33: 440 - 443.
- Fridel G., Wurst H. et al. (2001). Die endoluminaletherapie in trachea und bronchus. *Chirurg*; 72: p. 1119-1129.
- Grillo H.C. (2003). Development of tracheal surgery: a historical review. Part 2: treatment of tracheal diseases. *Ann. Thorac. Surg.*, 75: 1039 - 1047.
- Han S. (2009). E-Comment: New technique in tracheal reconstruction. *Interactive Cardiovascular and Thoracic Surgery*, 9(3): 449 - 449.
- Gavrilova AK, Cibikdorjiev BD. (2009). Endoscopic diagnostic of cicatricial stenosis of tracheal and larynx, prognosis and treatment tactics. *Bulletin of Siberian Scentific center of Russian academy of science*, 3: 315-316.
- Gasanov AM, Osipov AS, Pinchuk TP. (2010). Damages of larynx and trachea. *Endoscopic surgery*, 16(2): 55-60.
- Gyusan AO, Gyusan SA. (2004). Etiology of tracheal stenosis in patients of ICU. *Russian Journal of otolaryngology*, 5: 64-66.
- Kirasirova EA, Ejova EG. (2004). To the question of tracheostomy in patients of prolonged ventilation. *Journal of otolaryngology*, 6: 55-57.
- Kotiv BN, Popov BN. (2012). Surgical anatomy of changes caused by cicatricial stenosis of trachea. *Journal of Russian Military Medical academy*, 1: 40-43.
- Kubishkin CI, Gorbunov VA. (2006). Tracheostomy procedure: mistakes and complications. *Military medical Journal*, 11: 30-36.
- Lafutkina NV. (2007). Tactic of treatment of patients after tracheostomy in ICU. *Surgery*, 6: 30-33.
- Leontyev AS, Korotkevich AG. (2012). Early endoscopic treatment in prophylactic of postintubational complication in trachea. *Journal named of Sklifosovsky Urgent Care*, 3: 12-15.
- Novikov BN, Trishkin DV. (2008). Risk factors of development of postintubational complication on trachea and larynx. *Russian otolaryngology journal*, 6: 95-98.
- Parshin VD. (2007). Social and medical aspects of cicatricial tracheal stenosis. *Russian medical news*, 12(4): 49-52.
- Parshin VD, Porhanov VA. (2010). Surgery of trachea with atlas of procedures. Moscow, «Aldi-print», 480 (book in russian).
- Rusakov MA, Parshin VD, Elezov AA. (2006). Modern methods of endoscopic treatment of cicatricial tracheal stenosis. *J. Problems of TB and lungs diseases*, 3: 11-17.
- Serebrennikova EV, Korotkevich AG. (2011). Postitubational complications after prolonged artificial lung ventilation. *Polytrauma*, 2: 48-52.
- Tatur AA, Leonovich SI. (2011). Radical surgical treatment of cicatricial tracheal stenosis. *Moscow journal of surgery*, 1: 8-12.
- Vereschagina OE. (2010). Endoscopy of cannulaholders. *Russian otholaringology*, 1: 3-8.
- Vijigina MA, Gudovskiy LM, Parshin VD. (2001). Postreanimationcicatricial tracheal stenosis: cause, prophylactic and emergency help. *Anesthesiology and reanimatology*, 3: 33-37.
- Yaitsky NA, Gerasin VA. (2012). Role of endoscopic methods in treatment of cicatricial tracheal stenosis. *Surgery*, 3: 11-15.
- Zenger VG, Inkina AV, Komarova JE. (2006). Problem of treatment of patients with tracheal and laryngeal stenosis from the point of view of laryngologist. *Journal of problems of TB and lungs diseases*, 3: 28-33.