

SURGICAL TREATMENT WITH NONUNION OF THE LATERAL HUMERAL CONDYLE OF HUMERUS WITH CUBITUS VALGUS IN CHILDREN USING ILIZAROV APPARAT



Ilkhom E. KHUJANAZAROV, Iskandar U. KHODJANOV

Department of Orthopedic Trauma Surgery for Children
of Scientific-Research Institute of Traumatology and Orthopedics, Tashkent, Uzbekistan

ABSTRACT

Background. Nonunion of the lateral humeral condyle are of the complex pathology of the elbow joint, occurring relatively often and resulting in disability of children.

The treatment of nonunion of the lateral humeral condyle of humerus with cubitus valgus remains controversial. Purpose of this report was improvement of the results of surgical treatment of the nonunion of the lateral humeral condyle of humerus with cubitus valgus of the lateral humeral condyle of humerus with cubitus valgus with use of differential approach to the surgical strategy.

Material and methods. We were observing 28 children (17 boys and 11 girls) with nonunion and long-standing nonunion of lateral condyle of humerus, with various degrees of severity. There were used MRI and X-ray investigations for differential study of the patients divided into 3 groups in relation to stability and non-stability of the nonunion of the lateral humeral condyle of humerus with cubitus valgus of the lateral humeral condyle of humerus with cubitus valgus.

Results. All 28 patients lateral humeral condyle nonunions with cubitus valgus achieved union within sixty five days after operative procedure using Ilizarov's technique. The mean postoperative humerus-ulna angle was 6,0 degrees of cubitus valgus. All of reverse T-osteotomies healed uneventfully, and there was no loss of correction postoperatively. The mean duration of follow-up was 7 years. The overall results were excellent in 15(53,5%) patients, good in 11(39,3%) patients, and fair in 2(7,2%) patients. All 28 patients lateral humeral condyle nonunions with cubitus valgus achieved union within sixty five days after operative procedure using Ilizarov's technique. The mean postoperative humerus-ulna angle was 6,0 degrees of cubitus valgus. All of reverse T-osteotomies healed uneventfully, and there was no loss of correction postoperatively. The mean duration of follow-up was 7 years. The overall results were excellent in 15(53,5%) patients, good in 11(39,3%) patients, and fair in 2(7,2%) patients.

Conclusion. We believe it is reasonable to use our treatment method when dealing with nonunion of the lateral humeral condyle with cubitus valgus. These differential techniques helps to shape the distal part of humerus, thus, restoring the function of the elbow joint.

UDC Code & KEYWORDS

■ 616.727.3-053-001.59-007.24-089.84 ■ HUMERUS ■
ILIZAROV ■ HUMERAL CONDYLE ■

INTRODUCTION

The treatment of nonunion of the lateral humeral condyle of humerus with cubitus valgus remains controversial[1,3,5]. Improper location of fragments violates anatomic integrity of the segment, the form and the function of an important and complex joint such as an elbow joint. Given that the

treatment concerns of the new fractures of the lateral condyle of humerus are widely enlightened in literature, the concerns of treatment of long-standing nonunion of lateral humeral condyle with cubitus valgus are still poorly studied[2,4]. In the meantime, the cohort of such patients makes a relatively high percentage, which is, on one hand, due to overestimation of elastic possibilities in child's age, and, on the other hand, due to mistakes in diagnostics, treatment and rehabilitation.

Nonunion of the lateral condyle of humerus represent severe injuries of this anatomical structure and lead to disability of children and teenagers. Eventually, aseptic necrosis of lateral section of distal end of humerus with the loss of its articular structures of humerus occurs. In many cases, the part of trochlea of humerus is resolved. Absence of lateral support (dislocation of the head of condyle of humerus, aseptic necrosis of the section, or of the entire trochlea of humerus) results in valgus deformity of the elbow joint with tardy ulnar nerve palsy[1]. With time, the fossa olecranon, part of the trochlea and the head of radius get out of shape. Progressing deformation of these elements aggravates the valgus and results in late neuritis of the ulnar nerve. Occurrence of similar pathology in child's age requires multistage surgical interventions, which result in loss of functional possibilities of the elbow joint. With the growth of children this pathology increasingly gets to be a social problem since the patients get disabled.

MATERIALS AND METHODS

We were observing 28 children (17 boys and 11 girls) with nonunion and long-standing nonunion of lateral condyle of humerus, with various degrees of severity. The first I- group comprised 9(32,1%) children, the second II- group – 8(28,6%), and the third III-group – 11(39,3%) children. It was clear that during the initial examination the majority of children had insignificant dislocations of bone fragments or they didn't have them. What caused the progression of the nonunion of lateral humeral condyle was the active functional treatment, while still with un-united fracture, and rudimentary dislocations after the reduction of the bone fragments. The restoration of the lateral condyle by means of fibroid adhesion is insufficiently reliable in order to withstand the continuous pressure of the radius. As a consequence of the dislocation of fragments of the lateral condyle of humerus, the blood supply disturbance of lateral surface of the distal part of humerus is progressing and the humerus is subjected to aseptic necrosis and deformation in the form of cubitus valgus. Sometimes, the deformation angle may reach 60 degrees. In the presence of frank cubitus valgus, n. ulnaris is extended and this strain results in its with tardy ulnar nerve palsy[1,3], which is manifested by way of pain syndrome. Average time for post-injury visits of children is four years (from 2 to 8 years).

EVALUATION

The humero-ulnar-wrist angle was measured on anteroposterior X-rays. To measure the humero-ulnar-wrist

angle, we first drew two transverse lines (one proximal and one distal) across the forearm that connected the medial cortex of the ulna and the lateral cortex of the ulna and the lateral cortex of the radius. We then drew a line connecting the midpoints of the two cross-humeral lines and another connecting the midpoints of the two lines across the forearm. These lines were extended until they intersected, and the angle of intersection was measured with a goniometer.

Depending on relation of dislocation of the lateral condyle of humerus to distal part of the humerus, we are proposing the following degrees of severity of progressing deformation:

I-degree: Radiological signs: the lateral condyle of humerus is on the level of its maternal bed, but, there are characters of aseptic necrosis of the latter; slight, under 10 degrees valgus deformation of elbow joint; actual changes of the lateral condyle of humerus are not defined; and, there is a rotation of the lateral condyle of humerus. Clinically, the lateral condyle is mobile only under palpation, barely protruding under the skin. The function of the elbow joint is slightly limited range of motion(ROM), there are no severe symptoms such as atrophy of the intrinsic muscles of the hand, although hypesthesia in the fourth fifth digits.

II-degree: Radiologically: The lateral condyle of humerus is de-centered, rotated, there is the aseptic necrosis of the lateral condyle of humerus, but part of the fossa olecranon and the trochlea preserve their anatomical shape. There is a porosity of the lateral condyle of humerus. Clinically, the lateral condyle of humerus deforms the shape of the joint, and is mobile when working out the joint. Patients feel pain with the load on the joint and decrease of muscle power of this extremity. Valgus deformation of elbow joint under 25 degrees, and there are under 40 degrees limitations of ROM of elbow joint;

III-degree: Radiologically: The lateral condyle of humerus is outside the articular surface of elbow joint, rotated, the trochlea of humerus is absent, the chelidon is deformed and acquiring an oblique and oval shape, there are aseptic changes in the distal section of the humerus, and, specifically, over its lateral surface, the olecranon of ulna and the head of radius are changed repeatedly, there are osteoparotic changes of all bone elements of elbow joint; And clinically, there is a rough valgus deformation of elbow joint, the lateral condyle of humerus is significantly protruding over the lateral surface of the elbow joint, it is mobile, painful under palpation, and cubitus valgus over 35 degrees - there are neurotrophic complications with peripheric changes.

OPERATIVE PROCEDURE

The operative procedure was performed with use two parallel by Sergey P. Mironov's[5] of a posteriolateral and posteriomedial approaches of elbow joint. Posteriomedial approach parallel to ulnar nerve, was used when anterior transposition of the ulnar nerve was necessary. We offered the tri-osteotomy correction of deformations for the first and the initial second severity degrees. We considered the following: the surface osteotomy of maternal surface of the lateral condyle of humerus, and supracondylar osteotomy of humerus on the level of reattachment of the lateral condyle of humerus to make the box for the elements of humerus, and osteotomy, and using autogenous bone-grafting of lateral condyle of humerus with further crossed fixation by Kirchner wires and apparatus of 0,5X0,5 rings of Ilizarov's apparatus (Patent № IDP 2000 0443/DF from 06.13.2000 "Treatment method of nonunion of the lateral of condyle of humerus in children").

The method was effective with the first and the second severity degrees of nonunion of lateral condyle of humerus. The distal part of the humerus was being restored in a short period of time after the adhesion of the lateral condyle of humerus, since there were no rough deformations in the joint, and aseptic necrosis of the distal part of the humerus didn't appear much. Using this method we operated on 17 children with good and positive dynamics of recovery of the shape of the elbow joint. The recovery period for full function of the joint was around two years.

For children with the third severity degree, the use of this method is not sufficient, because, there are rough deformations in the area of elbow joint and the defects of anatomical elements of the distal part of humerus with neurotrophic changes. There by, after a long selection of existing treatment methods, we developed the new technique of treatment of long-standing nonunion of lateral humeral condyle with cubitus valgus. The essence of the method is in maximal preservation of the soft-tissue blanket of the elements of the distal part of humerus, which works as a blood supplying object of this localization, with isolation of the ulnar nerve, with correcting osteotomy of the heel of humerus, with clearing of bone ends and fixation of all elements in the form of reverse "T"-osteotomy, autogenous bone-grafting with further crossed fixation by K-wires and apparatus of 0,5X0,5 rings of Ilizarov's apparatus (Patent №IAP 2005.0060 from 02.23.05, "Treatment method of long-standing nonunion of lateral condyle of humerus in children"). The duration of fixation of the apparatus depends on adhesion of bone elements. The initial results received after these reconstructive surgeries showed that the gradual formation of the elements of the distal part of humerus was occurring.

Therefore, only the surgical treatment may prevent the development of severe and delayed complications in children with long-standing nonunion of the lateral humeral condyle with frank aseptic necrosis of the distal part of humerus (progressing cubitus valgus, delayed neuritis of ulnar nerve and other). The surgical intervention should be ultimately conservative. During the separation of fragment from adhesions it is necessary to preserve the connection of fragment to the musculotendinous leg. Attachment of the fragment should be done by the external fixation apparatus preserving the function of the elbow joint, external support should be continued until the full consolidation appears (up to six weeks).

RESULTS

We used for evaluation of the functional results modification rating index of Broberg and Morrey. All 28 patients lateral humeral condyle nonunions with cubitus valgus achieved union within sixty five days after operative procedure using Ilizarov's technique. The mean postoperative humerus-ulna angle was 6,0 degrees of cubitus valgus. All of reverse T-osteothomies healed uneventfully, and there was no loss of correction postoperatively. The mean duration of follow-up was 7 years. The overall results were excellent in 15(53,5%) patients, good in 11(39,3%) patients, and fair in 2(7,2%) patients.

CONCLUSION

1. Nonunion of the lateral humeral condyle are of the complex pathology of the elbow joint, occurring relatively often and resulting in disability of children.
2. Short-term fixation of fractures and early forcible working-out cause the progression of non-unions and long-standing nonunion of the lateral condyle of humerus.

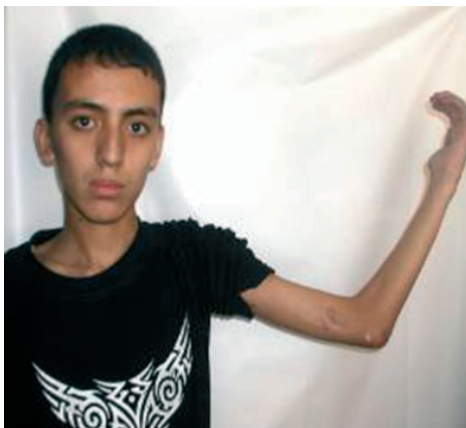3. We believe it is reasonable to use our treatment method when dealing with nonunion of the lateral humeral condyle with cubitus valgus. This technique helps to shape the distal part of humerus, thus, restoring the function of the elbow joint.

REFERENCES

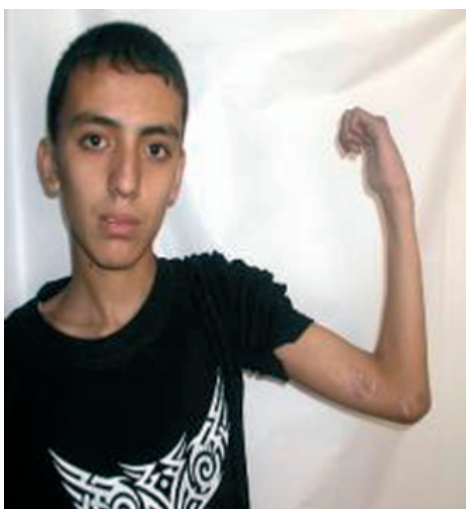1. Wilkins KE, Beaty JH, Chambers HG, Toniolo RM. Fractures and dislocations of the elbow region. In: Rockwood CA Jr, Wilkins KE, Beaty JH, editors. Fractures in children. 4th ed, vol 3. Philadelphia: Lippincott-Raven; 1996.p 653-904.
2. Schneider G, Pouliquen JC. [Old fractures of the lateral humeral condyle (lateralis capitellum humeri) in children]. Rev Chir Orthop Reparatrice ApparMot. 1992;78:456-63. French.
3. Shibata M, Yoshizu T, Tajima T. [Long-term results of osteosynthesis for established non-union of lateral humeral condyle in children]. Orthop Surg Traumat. 1992;35:1165-72. Japanese.
4. Shimada K, Masada K, Tada K, Yamamoto T. Osteosynthesis for the treatment of non-union of the lateral humeral condyle in children. J Bone Joint Surg Am. 1997;79:234-40.
5. Sergey P. Mironov Treatment of posttraumatic deformation and contractures of elbow joint in children and teenagers. Avtoreferat of dissertation for doctoral scientific degree of Medicine. Moscow, 1984, 37p.
6. Broberg MA, Morrey BF. Results of delayed excision of the radial head after fracture. J Bone Joint Surg Am. 1986;68:669-74.

APPENDIX

Picture 1a

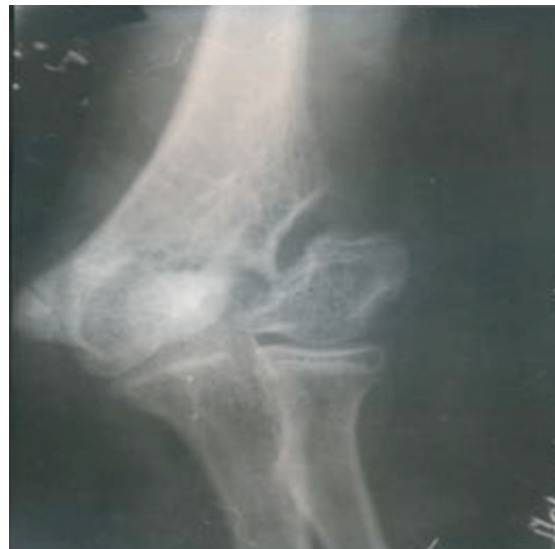


Picture 1b

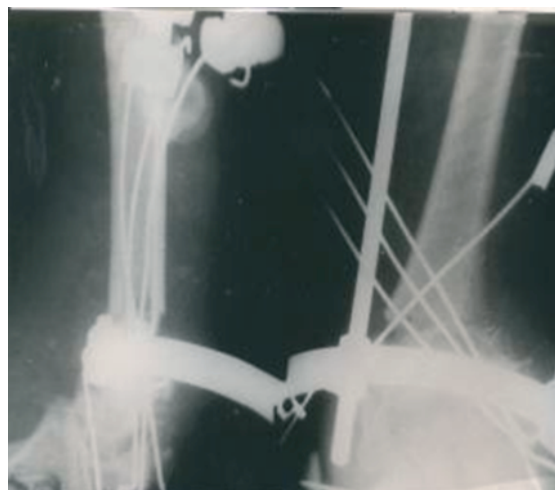


<http://health.journals.cz/>

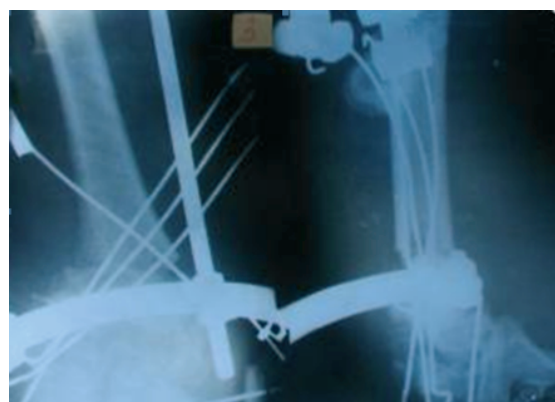
Picture 1c



Picture 1d

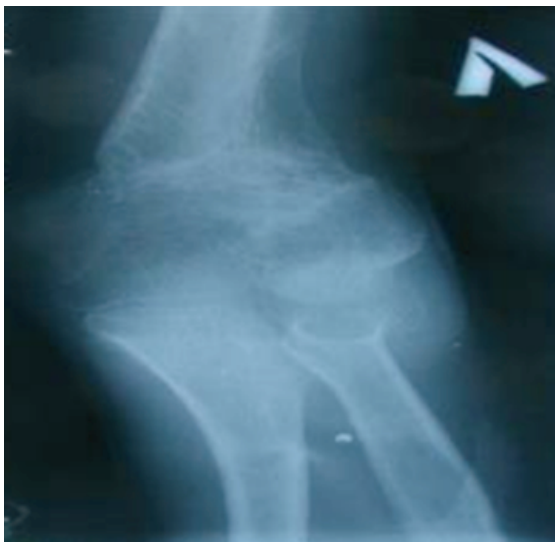

Picture 1e

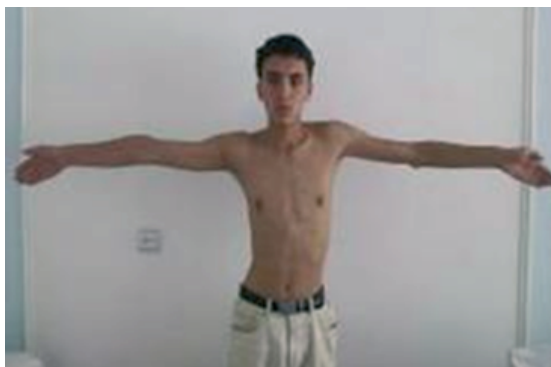


VOLUME 1, 2011

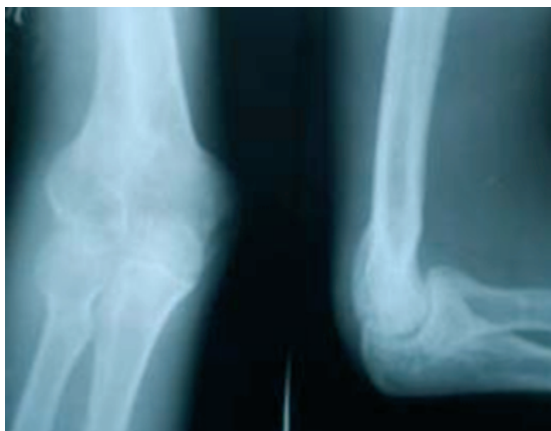
Picture 1f



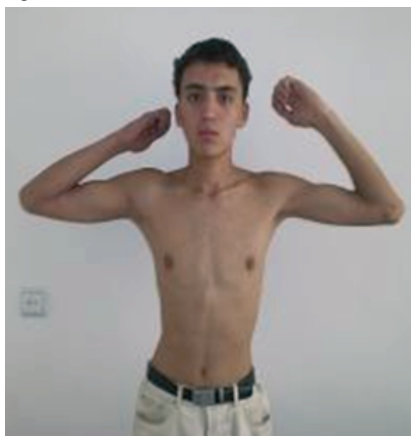
Picture 1i



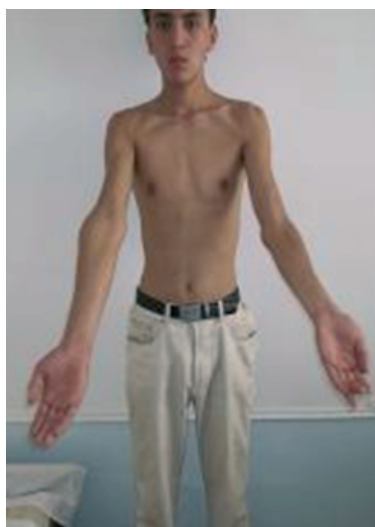Picture 1h



Picture 1g



Picture 1h



<http://health.journals.cz/>

